

**Angiostrongylus costaricensis n. sp. (Nematoda:
Metastrongyloidea), a new lungworm occurring in
man in Costa Rica**

by

Pedro Morera*, *** **and** **Rodolfo Céspedes****, ***

(Received for publication November 15, 1970)

Fourteen species of the genus *Angiostrongylus*, created by KAMENSKY (18), have been described, but among these only *A. cantonensis* (Chen, 1935) Dougherty, 1946 has been incriminated as a causal agent of disease in man. The first investigators who found this parasite in humans were Nomura and Lin in 1945 (BEAVER and ROSEN, 10). However, because the paper was published in Japanese, it failed to appear in the standard indexing and abstracting journals and this finding remained unknown until ROSEN *et al.* (24, 25), HORIO and ALICATA (17) and ALICATA (1, 2) established the real importance of this work by attributing eosinophilic meningitis to this parasite. Recent studies have shown that parasitized rats are found in most tropical zones, except those of Africa and the Americas (ALICATA, 6). ALICATA (3) searched unsuccessfully for *A. cantonensis* in Costa Rica. However, for several years we have had the opportunity to study a clinico-pathological picture, observed mainly in children, characterized by the formation of granulomas with heavy eosinophilic infiltration in the abdominal cavity. We propose the name *Angiostrongylus costaricensis*, n. sp. for the etiological agent of this disease, because this parasite has many morphological characteristics that distinguish it from the other species of the genus.

MATERIAL AND METHODS

Surgical specimens obtained from several hospitals of the country were used in this study. From fixed material the worms were obtained by dissecting

* Department of Parasitology, University of Costa Rica.

** Department of Pathology, University of Costa Rica.

*** Division of Pathology, San Juan de Dios Hospital, San José.

the small arteries of the intestinal wall and in unfixed specimens they were liberated by digestion with pepsin. Drawings were made with the aid of a camera lucida. Measurements are given in millimeters unless otherwise specified.

Angiostrongylus costaricensis n. sp.

(Figs. 1-7)

DESCRIPTION: Angiostrongylinae, Böhm and Gebauer, 1934; *Angiostrongylus* Kamensky, 1905.

Body filiform in both sexes, tapering toward both ends. The caudal end of the male curves ventrally, with a well developed copulatory bursa; in the female the caudal end is roughly conical and slightly curved. Cuticle transversely striated and thicker toward both ends. Excretory pore immediately posterior to the base of the club-shaped esophagus.

MALE: (3 specimens): Body length 15.0 to 17.9; width at the esophageal-intestinal junction 0.079 to 0.093; esophagus 0.160 to 0.180. Spicules slender, equal, striated, ending in two hook-shaped formations, 0.267 to 0.297 in length. Gubernaculum present, 0.045 long. This structure was not identified in a preliminary study (MORERA, 21). In the copulatory bursa ventral rays fused except for the distal fifth, with bud-shaped endings; the ventrolateral is slightly longer than the ventroventral. The lateral rays arise from a common trunk and are of similar size, the posterolateral and mediolateral are fused in the proximal half and the externolateral separates from these after its emergence from the common trunk. The externodorsal ray arises near the base of the laterals and is separate from the dorsal; it is long, slender, and larger at the distal end. The dorsal ray is thick, short, terminating in three tips; the central one is short, knob-like, and the laterals beak-shaped.

FEMALE (1 specimen): Body length 26.9; width at base of esophagus 0.108; esophagus 0.165. "Barber-pole" appearance of the reproductive apparatus coiled around the intestine, typical of the genus, not prominent in the fixed material. Vulva situated 0.175 and anus 0.053 from tip of tail; caudal end almost cone-shaped; tip of tail bears a small refringent spine.

HOST: Man is not considered to be the normal host; animal hosts are as yet unknown. Normal habitat: unknown. In man the worms are localized in small branches of the mesenteric artery.

Type specimens: Holotype male, allotype female, Department of Parasitology, University of Costa Rica.

DISCUSSION

In 1967, ASH (7) mentioned ten species of the genus *Angiostrongylus*, in addition to *A. michiganensis* described by him; he did not mention *A. sciuri* described by MERDIVENCI (20). More recently two other species have been described: *A. sandarsae*, Alicata, 1968 and *A. mackerrasae*, Bhaibulaya, 1968.

A comparative study of these fourteen species with the parasite found in Costa Rica revealed many characteristic differences whose point by point description would be too long to include here. Therefore, we have limited ourselves only to the description of the most important differences, which in our opinion justify the establishment of a new species. In the first place, on the basis of the parasite size, we are able to ignore all those whose length is less than one half that of *A. costaricensis*: *A. blarini*, Ogren, 1954; *A. ondatrae*, Schultz, Orlow and Kutass, 1933; *A. soricis*, Soltys, 1954; and *A. michiganensis*, Ash, 1967.

The length of the spicules, an important taxonomic character, permits us to disregard all those species in which these structures measure more than 0.400; this dimension being much greater than the maximum of 0.297 found in *A. costaricensis*. These species are *A. cantonensis*, Chen, 1935; *A. gubernaculatus*, Dougherty, 1946; *A. tateronae*, Baylis, 1928; *A. chabaudi*, Biocca, 1957; *A. sciuri* and *A. mackerrasae*.

The spicules of *A. vasorum* (Baillet, 1866) Kamensky, 1905 (considered by most authors to be synonymous with *A. raillieti*, Travassos, 1927), although a little shorter than 0.400, are still longer than those of *A. costaricensis*; the original description by Baillet (1866) and the redescription by CABRAL-GONÇALVES (13) allow us to establish other important differences; these are that the vulva is further from the tip of the tail in *A. vasorum* and that the tail is roughly conical in *A. costaricensis* and rounded in the other two. *A. sandarsae* has relatively longer spicules and a notably longer esophagus. There were also appreciable differences in the morphology and distribution of the bursal rays, especially the size relationship between the lateroventral and the ventroventral, and in the form and origin of the externodorsal.

We think that *A. ten*, Yamaguti, 1941, is not an acceptable species, because until now a male has not been described.

An important characteristic is the presence of a conspicuous spine at the tip of the tail of the female of *A. costaricensis*. A similar structure occurs only in *A. mackerrasae*.

Another important characteristic is the presence of a gubernaculum in *A. costaricensis*. The first species described with this structure was *A. ondatrae*; however, BAYLIS (9) in the description of *A. tateronae* mentioned that the dorsal wall of the cloaca appeared thickened and chitinised. Although he interpreted this area as a telamon, it is more than likely a gubernaculum.

In 1946, DOUGHERTY (16) in describing *A. gubernaculatus*, stated erroneously that it was the first species that had a gubernaculum. Recently, ALICATA (4) described another species with a gubernaculum, *A. sandarsae*, and

later the same author described this structure in *A. cantonensis* (ALICATA, 5). The presence of a gubernaculum in *A. gubernaculatus* and *A. ondatrae* served as the basis on which SKRJABIN *et al.* (27) classified these parasites into the genera *Angiocaulus* and *Rodentocaulus*, respectively. The latter had been originally classified in this way by SCHULTZ *et al.* (26). Working with Ash (unpublished data), it was found that careful examination of *A. vasorum* revealed the presence of a gubernaculum and recently, Bhaibulaya has found a gubernaculum in *A. mackerrasae* (ASH, personal communication).

In 1952, the first Costa Rican case of the disease caused by this parasite was observed (CÉSPEDES *et al.*, 14; MORERA, 21) and since then, more than 70 cases have been studied. The main symptoms (ROBLES *et al.*, 23) were abdominal pain, usually localized in the right iliac fossa. Fever was usually high and sometimes lasting up to two months. Anorexia was often observed and one third of the patients experienced vomiting. The physical examination showed an intra-abdominal mass which could cause confusion with malignant tumors or acute appendicitis of other etiology. Rectal examination was usually painful and sometimes the tumoral mass could be palpated. The most important laboratory findings were leucocytosis ranging from 10,000 to 52,000 per mm³ with eosinophilia from 11 to 81 per cent. In a few cases, eosinophilia was lower than 10 per cent. X-ray examination showed alteration of the intestinal wall as demonstrated by a filling defect (Fig. 9), spasticity and irritability (Stierling's sign) as well as a festooned aspect of the mucosa.

Anatomo-pathological studies revealed that lesions were, in most cases, localized in the appendix, but some were found to extend to the terminal portion of the ileum, cecum, the first part of the ascending colon, and to the regional lymph nodes (14). The main characteristic was thickening and hardening of the edematous intestinal wall, with millary yellowish granulomatous infiltration. These lesions could produce incomplete or complete obstruction. In some cases, necrotic processes could produce perforation. Less frequently, lesions were observed in the transverse and descending colon and sigmoid. Histologically the lesions appeared as a granulomatous inflammation with massive eosinophilic infiltration, involving all the layers of the intestinal wall. This same inflammatory process was observed to affect the regional lymph nodes. Thin-shelled, oval, embryonated eggs were scattered in the lesion (Fig. 8). Occasionally, the embryos reached the larval stage, but the larvae remained enclosed within the egg shell (Fig. 10). In cases of longer evolution, the eggs appeared inside the giant cells. Sections of the adult parasite could be found in both mesenteric arteries and their intramural branches (Fig. 11). These worms sometimes produced arteritis and thrombosis (Fig. 12).

A. costaricensis is the second species of the genus to be found in man and there is a clear difference between the disease produced by it and the eosinophilic meningoencephalitis produced by *A. cantonensis*. We believe this difference is caused by different life cycles, known only for *A. cantonensis* (MACKERRAS and SANDARS, 19). In any case, *A. costaricensis* appears to adapt better to man, as demonstrated by the presence of adult worms in the arteries, and em-

MORERA & CÉSPEDES: ANGIOSTRONGYLUS COSTARICENSIS, N. SP. 177

byronated eggs in the tissues. However, the larvae apparently do not hatch, which suggests the impossibility of these larvae ever entering the intestinal lumen and returning to the soil to complete their life cycle. In the human cases in which we have had the opportunity to screen the feces for larvae, the results were negative.

ACKNOWLEDGEMENTS

The authors are indebted to Dr. Lawrence R. Ash, School of Public Health, UCLA, for his kindness and helpful criticism in preparation of the text. We also express our appreciation to Dr. Alfonso Trejos, Dr. Alan Altman and Dr. Thomas Lau for their help in preparation of the English manuscript.

SUMMARY

Angiostrongylus costaricensis n. sp. is described from Costa Rica where it produces lesions in the abdominal cavity of man. It can be distinguished from other species of the genus on the basis of its size, the length of the spicules, the position of the vulva and the morphology and position of the bursal rays. The parasite localizes in the small mesenteric arteries, especially in the ileocecal region, where it produces arteritis and thrombosis. Eggs in various stages of embryonation were found scattered in the tissues of the intestinal wall and regional lymph nodes, eliciting a granulomatous inflammatory reaction with intense eosinophilic infiltration.

RESUMEN

Los autores hacen la descripción de *Angiostrongylus costaricensis* n. sp., un nuevo metastrongilideo encontrado en Costa Rica, que produce lesiones en el hombre. Esta nueva especie se puede distinguir de las otras catorce descritas hasta ahora, en base a su tamaño, la longitud de las espículas, la posición de la vulva y la morfología y disposición de los rayos bursales. *A. costaricensis* es la segunda especie del género de importancia en parasitología humana. La otra especie patógena para el hombre, *A. cantonensis*, es responsable de una forma de meningoencefalitis eosinofílica.

Los parásitos adultos, machos y hembras, se localizan en las arterias del mesenterio y de la pared intestinal, especialmente de la región ileocecal en donde provocan fenómenos inflamatorios y trombóticos que llevan a grados diversos de necrosis. La presencia de huevos en varios estados de embrionación, en el tejido de la pared intestinal y de los ganglios linfáticos regionales, produce una reacción inflamatoria granulomatosa con intensa infiltración eosinofílica. La pared intestinal se presenta engrosada, llegándose a producir cuadros de suboclusión u oclusión que obligan a intervenciones quirúrgicas de emergencia.

La presencia de huevos en los tejidos humanos sugiere una mejor adap-

tación de *A. costaricensis* en el hombre, en comparación con *A. cantonensis*, que no llega a alcanzar el estado adulto en los tejidos encefálicos humanos. Sin embargo en los casos en que hemos encontrado larvas completamente formadas, ellas siempre están encerradas en la cáscara del huevo, lo que sugiere la imposibilidad de que las mismas lleguen a la luz intestinal y regresen al suelo para completar su ciclo de vida.

LITERATURE CITED

1. ALICATA, J. E.
1961. A cause of parasitic meningitis in the Pacific—rat lungworms. *Hawaii Farm. Bur. J.*, 1-2 (Special Number).
2. ALICATA, J. E.
1962. *Angiostrongylus cantonensis* (Nematoda: Metastrongylidae) as a causative agent of eosinophilic meningitis of man in Hawaii and Tahiti. *Canad. J. Zool.*, 40: 5-8.
3. ALICATA, J. E.
1967. Absence of *Angiostrongylus cantonensis* among rodents in parts of Central America and South America. *J. Parasitol.*, 53: 1118.
4. ALICATA, J. E.
1968a. *Angiostrongylus sandarsae* sp. n. (Nematoda: Metastrongyloidea) a lung-worm of rodents in Mozambique, East Africa. *J. Parasitol.*, 54: 896-899.
5. ALICATA, J. E.
1968b. The gubernaculum of *Angiostrongylus cantonensis* (Chen). *J. Parasitol.*, 54: 1193.
6. ALICATA, J. E.
1969. Present status of *Angiostrongylus cantonensis* infection in man and animals in the tropics. *J. Trop. Med. Hyg.*, 72: 53-63.
7. ASH, L. R.
1967. *Angiostrongylus michiganensis* sp. n. (Nematoda: Metastrongyloidea), a lung-worm occurring in the shrew, *Sorex cinereus cinereus*, in Michigan. *J. Parasitol.* 53: 625-629.
8. BAILLET, M. C.
1866. *Nouveau Dictionnaire Pratique de Médecine, Chirurgie et d'Higiène Vétérinaires*, T. VIII: 587-588.
9. BAYLIS, H. A.
1928. On a collection of nematodes from Nigerian mammals (chiefly rodents). *Parasitology*, 20: 280-304.
10. BEAVER, P. C., & L. ROSEN
1964. Memorandum on the first report of *Angiostrongylus* in man by Nomura and Lin, 1945. *Amer. J. Trop. Med. Hyg.*, 13: 589-590.

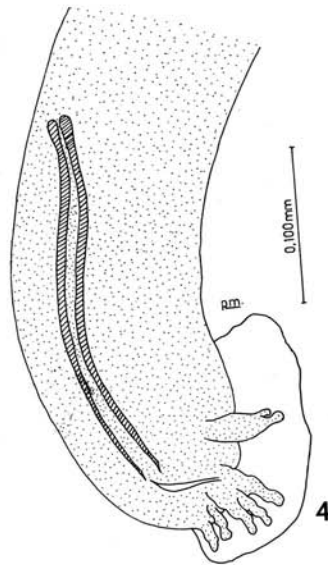
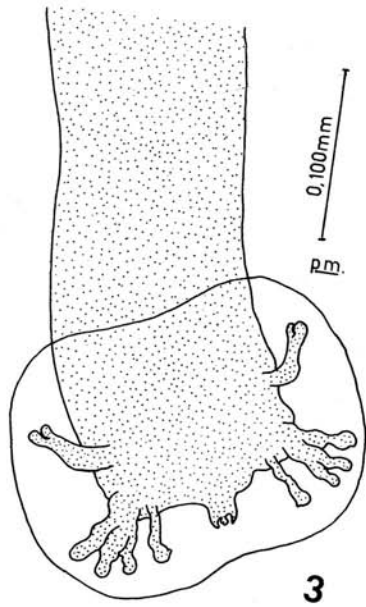
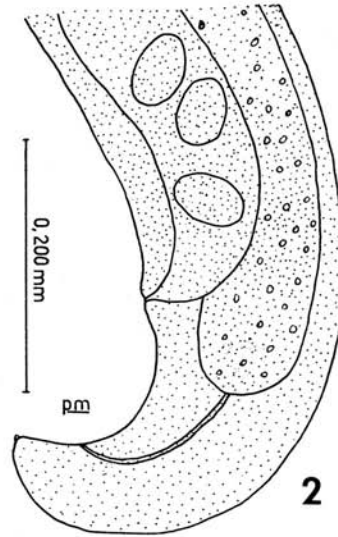
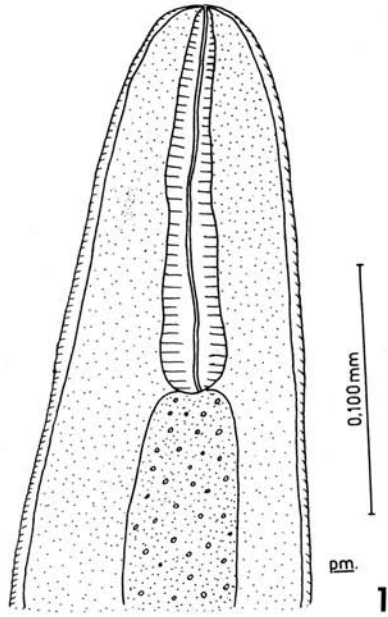
MORERA & CÉSPEDES: ANGIOSTRONGYLUS COSTARICENSIS, N. SP. 179

11. BHAIBULAYA, M.
1968. A new species of *Angiostrongylus* in an Australian rat, *Rattus fuscipes*. *Parasitology*, 58: 789-799.
12. BIOCCHA, E.
1957. *Angiostrongylus chabaudi* n. sp. parassita del cuore e dei vasi polmonari del gatto selvatico (*Felis silvestris*). *R. Accad. Naz. Lincei*, 22: 526-532.
13. CABRAL-GONÇALVES, P.
1961. *Angiostrongylus vasorum* (Baillet, 1866), novo parasito do cão no Rio Grande do Sul (Brasil) (Nematoda: Metastrongylidae) *Rev. Fac. Agron. Veter., P. Alegre*, 4: 35-40.
14. CÉSPEDES, R., J. SALAS, S. MEKBEL, L. TROPER, F. MÜLLNER & P. MORERA
1967. Granulomas entéricos y linfáticos con intensa eosinofilia tisular producidos por un estrongilideo (Strongylata) *Acta Méd. Costarric.*, 10: 235-255.
15. CHEN, H. T.
1935. Un nouveau nematode pulmonaire, *Pulmonema cantonensis*, n. g., n. sp. des rats de Canton. *Ann. Parasit. Hum. Comp.*, 13: 312-317.
16. DOUGHERTY, E. C.
1946. The genus *Aelurostrongylus* Cameron, 1927 (Nematoda: Metastrongylidae), and its relation with description of *Parafilaroides*, gen. nov. and *Angiostrongylus gubernaculatus* sp. nov. *Proc. Helminth. Soc. Wash.*, 13: 16-26.
17. HORIO, S. R., & J. E. ALICATA
1961. Parasitic meningoencephalitis in Hawaii, a new parasitic disease of man. *Hawaii Med. J.* 21: 139-140.
18. KAMENSKY, S. N.
1905. The systematic position of the genera *Haemostrongylus* Wost. and *Protostrongylus* g. n. among the other Strongylidae. *Sborn. Trud. Charkov Vet. Inst.* 7: 17-50 (in Russian).
19. MACKERRAS, MARY J., & DOROTHY F. SANDARS
1955. The life history of the rat lungworm *Angiostrongylus cantonensis* (Chen) (Nematoda: Metastrongylidae). *Austr. J. Zool.* 3: 1-21.
20. MERDIVENCI, A.
1964. A new lungworm *Angiostrongylus sciuri* n. sp. parasiting in the Venae Pulmonales of the squirrel, *Sciurus vulgaris*. *Rev. Fac. Sci. Univ. Istanbul. Ser. B-Sciences Naturelles* 29: 155-158.
21. MORERA, P.
1967. Granulomas entéricos y linfáticos con intensa eosinofilia tisular producidos por un estrongilideo (Strongylata; Railliet y Henry, 1913). II. Aspecto Parasitológico (Nota Previa) *Acta Méd. Costarric.*, 10: 257-265.
22. OGREN, R. E.
1954. A lungworm, *Angiostrongylus blarini*, n. sp. from the short-tailed shrew, with observations on the histopathology and life cycle. *J. Parasitol.*, 40: 681-684.

23. ROBLES, G., R. LORÍA, F. LOBO, A. ROBLES, S. VALLE & C. CORDERO
1968. Granuloma eosinofílico parasitario intestinal. *Rev. Méd. Hosp. Nal. Niños*, 3: 67-80.
24. ROSEN, L., J. LAIGRET & S. BORIES
1961. Observations on an outbreak of eosinophilic meningitis on Tahiti, French Polynesia. *Amer. J. Hyg.*, 74: 26-41.
25. ROSEN, L., R. CHAPPELL, G. L. LAQUEUR, G. D. WALLACE & P. P. WEINSTEIN
1962. Eosinophilic meningoencephalitis caused by a metastrongylid lungworm of rats. *J. Amer. Med. Assoc.*, 179: 620-624.
26. SCHULTZ, R. ED., VON, W. ORLOW & A. J. KUTASS
1933. Zur Systematik der Subfamilie Synthetocaulinae Skrj. 1932 nebst Beschreibung einiger neuer Gattungen und Arten. *Zool. Anz.*, 102: 303-310.
27. SKRJABIN, K. I., N. P. SHIKHOBALOVA, R. S. SCHULTZ, T. I. POPOVA, S. N. BOEV & S. L. DELYAMURE
1961. *Key to parasitic nematodes*, Vol. III. Strongylata (Transl. of 1952), 890 pp. Washington D. C.
28. SOLTYS, A.
1954. Helminthofauna ryjówkowatych (Soricidae) Białowieskiego Parku Narodowego. *Acta Parasit. Pol.*, 1: 353-402.
29. TRAVASSOS, L.
1927. Nematodeos novos. *Bol. Biol São Paulo*, 6: 52-61.
30. YAMAGUTI, S.
1941. Studies on the helminth fauna of Japan. Part 35. Mammalian nematodes, II. *Jap. J. Zool.*, 9: 409-439.

Figs. 1-4. *Angiostrongylus costaricensis* n. sp. 1. Anterior end. 2. Caudal end of the female showing the vulva, the anus and a little spine at the tip of the tail. 3. Male, ventral view. 4. Lateral view of the caudal end of the male, showing the bursa, the spicules and the gubernaculum.

MORERA & CESPEDES: ANGIOSTRONGYLUS COSTARICENSIS, N. SP. 181



Figs. 5-7. *Angiostrongylus costaricensis* n. sp. 5. Caudal end of the female. 6. Lateral view of the bursa showing the gubernaculum. 7. Ventral view of the caudal end of the male.

Fig. 8. Mesenteric lymph node showing eggs in the cortical

MORERA & CESPEDES: ANGIOSTRONGYLUS COSTARICENSIS, N. SP. 183

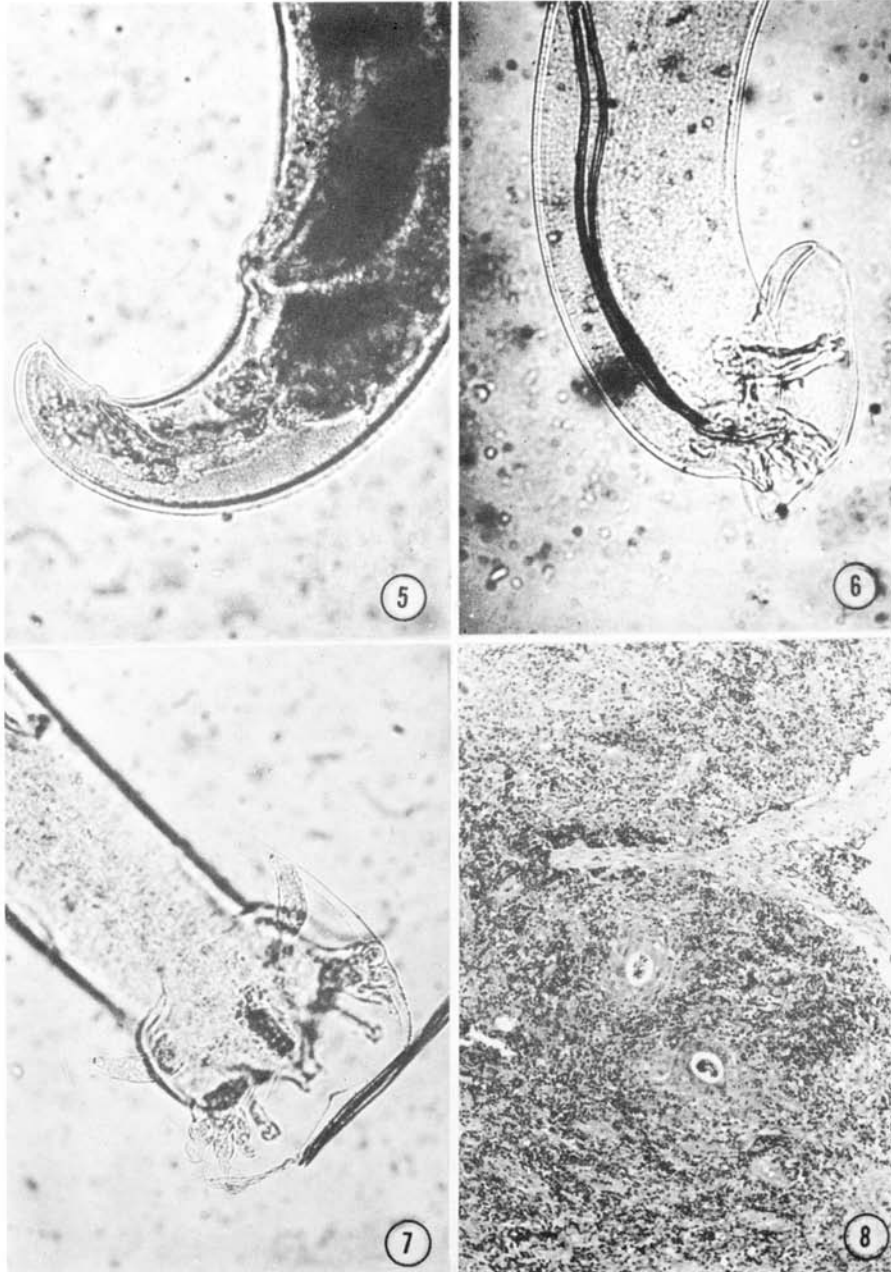


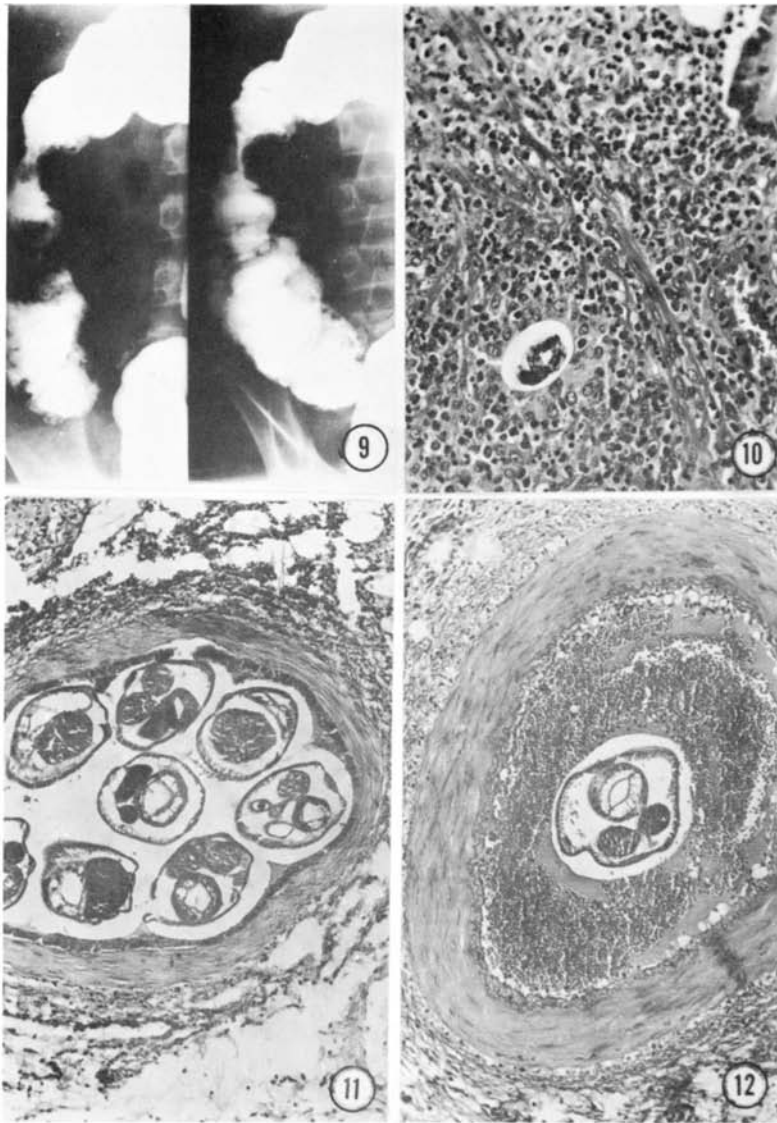
Fig. 9. X-ray of the abdominal cavity showing the filling defect of the ascending colon caused by the granuloma.

Fig. 10. Embryonated egg just below the muscularis mucosae of the colon.

Fig. 11. Small artery of the mesoappendix showing several sections of parasites.

Fig. 12. Small artery of the cecum wall showing complete occlusion by the presence of a thrombus that is in relation with a worm.

MORERA & CESPEDES: ANGIOSTRONGYLUS COSTARICENSIS, N. SP. 185



MORERA & CESPEDES: ANGIOSTRONGYLUS COSTARICENSIS, N.SP. 185 A

ADDENDUM

1. This work was originally submitted for publication to the *journal of Parasitology*.
2. Subsequently the definitive and intermediate hosts of *Angiostrongylus costaricensis* were found.
3. The complete study was presented at the Second Latin American Congress of Parasitology held in Mexico City in September, 1970.
4. Immediately after the Congress, two research notes were sent to *Boletín Chileno de Parasitología* reporting the discovery of the definitive and intermediate hosts of *A. costaricensis*. These notes were published in volume 25, 1970, which was behind schedule and appeared in 1971.
5. After having sent the research notes to *Boletín Chileno de Parasitología* the present manuscript was returned by the editors of *Journal of Parasitology* with a series of suggestions for changes which in our opinion not only altered its form, but also its content. We therefore decided to withdraw it from this journal and submitted it for publication in *Revista de Biología Tropical*, published by the University of Costa Rica, which at the time was in press (volume 18, 1970). However, this volume also fell behind schedule and was subsequently published in 1971, bearing this date, actual date of publication and not that of 1970 which correponds to volume 18.
6. Consequently the actual chronological order of both the research notes, and the present study should be:
 - a. The description of the new species in which the hosts were unkown; *Rev. Biol. Trop.*; 18, 1971; and
 - b. discovery of these hosts, *Bol. Chil. Parasitol.* 25, 1970.